

the rarely occurring intracranial sarcomas such as fibrosarcoma and synovial sarcoma. So far, there are no direct signs of clinical symptoms, and imaging could aid in the diagnosis of this rare tumor; the postoperative pathology is the only way.

The treatment of choice is surgery, but postoperative radiotherapy and chemotherapy are part of adjunctive therapy.<sup>11</sup> Gross total resection of the tumor is the most important therapeutic goal. Wide excision or amputation may be required in some cases. When radical tumor removal is not possible, excision combined with high-dose radiation and chemical therapy seems to be the best alternative treatment. In our case, the patient underwent once of chemotherapy and twice of gamma radiotherapy. During the 2 years' follow-up, the patient is still alive and without any complication.

The survival rate is very low. In the review, 66% of patients died, whereas 19% are alive with or without complications.<sup>12</sup> In general, grade II tumors typically survive more than 5 years, and those with grade III tumors survive 2 to 3 years. The prognosis of patients with World Health Organization grade IV tumors depends largely on whether effective treatment regimens are available. For MPNST, survival rate was better in patient treated with adjuvant chemotherapy and radiotherapy. Our patient had an uneventful postoperative course and had remained functional for 2 years, and we attribute this favorable outcome to the complete resection of tumor and the chemotherapy and radiotherapy he received after.

## CONCLUSIONS

Malignant peripheral nerve sheath tumor is a rare and aggressive tumor. Compared with other tumors, there is no typical representation in symptoms, signs, and image. The pathology is the only way to diagnose this kind of tumor. Because it is aggressive, we should consider the possibility of an MPNST when a tumor occurs in some special location, such as CPA in our case. A need for a multidisciplinary approach with the surgery of gross total resection, high-dose of chemotherapy, and radiotherapy is anticipated in the management of MPNST.

## ACKNOWLEDGMENTS

*The authors thank the patient and his family members who agreed to report this rare disease to help more patients. They also thank the doctors in the Departments of Pathology and Radiology for providing clear pictures and also the staff of Journal of Craniofacial Surgery for reviewing the article.*

## REFERENCES

- Hajdu SI. Peripheral nerve sheath tumors. Histogenesis, classification, and prognosis. *Cancer* 1993;72:3549–3552
- Than KD, Ghori AK, Wang AC, et al. Metastatic malignant peripheral nerve sheath tumor of the cauda equine. *J Clin Neurosci*. 2011;18:844–846
- Cashen DV, Parisien RC, Raskin K, et al. Survival data for patients with malignant schwannoma. *Clin Orthop Relat Res* 2004;426:69–73
- Aydin MD, Yildirim U, Gundogdu C, et al. Malignant peripheral nerve sheath tumor of the orbit: case report and literature review. *Skull Base* 2004;14:109–113
- Hedeman LS, Lewinsky BS, Lochridge GK, et al. Primary malignant schwannoma of the Gasserian ganglion. Report of two cases. *J Neurosurg* 1978;48:279–283
- Melliou A, Karamouzis J, Helis L, et al. Malignant peripheral nerve-sheath tumor of the left cerebello-pontine angle: case report. *J BUON* 2006;11:367–368
- Lee JH, Lee HK, Choi CG, et al. Malignant peripheral nerve sheath tumor in the parapharyngeal space: tumor spread through the eustachian tube. *AJNR Am J Neuroradiol* 2001;22:748–750
- Ziadi A, Saliba I. Malignant peripheral nerve sheath tumor of intracranial nerve: a case series review. *Auris Nasus Larynx* 2010;37:539–545
- Auclair PL, Langloss JM, Weiss SW, et al. Sarcomas and sarcomatoid neoplasms of the major salivary gland regions. A clinicopathologic and immunohistochemical study of 67 cases and review of the literature. *Cancer* 1986;58:1305–1315
- Zou C, Smith KD, Liu J, et al. Clinical, pathological, and molecular variables predictive of malignant peripheral nerve sheath tumor outcome. *Ann Surg* 2009;249:1014–1022
- Chao BH, Stogner-Underwood KA, Kiev J, et al. Intrathoracic malignant peripheral nerve sheath tumor in neurofibromatosis 1. *J Clin Oncol* 2008;26:2216–2218
- Frahm S, Mautner VF, Brems H, et al. Genetic and phenotypic characterization of tumor cells derived from malignant peripheral nerve sheath tumors of neurofibromatosis type 1 patients. *Neurobiol Dis* 2004;16:85–91

# Surgical Ciliated Cyst of the Medial Canthal Region After the Management of a Midfacial Fracture: A Case Report

Jingang An, MD, Yi Zhang, MD

**Abstract:** Surgical ciliated cysts are an uncommon complication of maxillary surgery. We report a case of such a cyst that developed at the right medial canthal region 10 years after the surgical treatment of a severe midfacial fracture. The cyst presented as a round cystic lesion protruding through a small bony defect. The lesion was completely excised, and histologic result showed a pseudostratified ciliated epithelial lining.

**Key Words:** Ciliated cyst, maxillofacial trauma, facial fracture, case report, surgery

Surgical ciliated cysts were first reported in the Japanese literature, and instances have since been reported with increasing frequency by clinicians in Western countries. Generally, it is believed that surgical ciliated cysts occur at the maxilla, that they are related to maxillary sinus surgery, and that the maxillary sinus mucosa is implanted into the surgical region; therefore, the cyst is generally known as a postoperative maxillary cyst.<sup>1</sup> Surgical ciliated cysts after maxillofacial trauma and cysts that occur at the medial canthal area are relatively rare. Herein, we report a case of a patient who developed a surgical ciliated cyst at the medial canthal region 10 years after the surgical management of a midfacial fracture.

## CLINICAL REPORT

A 42-year-old man presented with a slow-growing mass at the right medial canthal region. Three years ago, he had found the lesion at

From the Department of Oral and Maxillofacial Surgery, School and Hospital of Stomatology, Peking University, Beijing, People's Republic of China.

Received November 28, 2013.

Accepted for publication December 28, 2013.

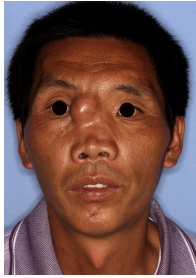Address correspondence and reprint requests to Jingang An, MD, Department of Oral and Maxillofacial Surgery, School and Hospital of Stomatology, Peking University, 22 Zhongguancun Nandajie, Haidian District, Beijing, People's Republic of China; E-mail: anjingang@126.com

The authors report no conflicts of interest.

Copyright © 2014 by Mutaz B. Habal, MD

ISSN: 1049-2275

DOI: 10.1097/SCS.0000000000000675



**FIGURE 1.** Preoperative photograph showing a round cystic lesion at the right medial canthal region.

the right medial canthal region that was the size of a peanut. During the past 3 years, the mass had grown slowly, and the patient eventually sought treatment because the mass was affecting his vision. There was no pain, numbness, blocked nose, headaches, or any other symptoms. Ten years ago, the patient had sustained a severe midfacial fracture in a traffic accident and had undergone an operation to manage the fracture.

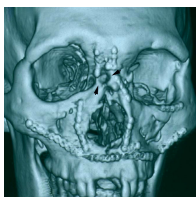
On examination, a round mass was noted at the right medial canthal region. The diameter of the mass was approximately 2.5 cm, it was soft and mobile, and the overlying skin was normal in appearance and texture (Fig. 1). He had normal visual acuity and normal eye activity, with no epiphora. Computed tomographic (CT) scan of the head showed a round bony defect at the upper part of the right frontal process of maxilla and nasal bone. The ethmoid sinus was deep to the bony defect, and there was no sign of infection (Fig. 2).

Surgery was performed under general anesthesia. The mass was exposed through a skin incision, and the capsule of the mass was completely mobilized. The tumor was cystic, and the cyst fluid was yellow and slimy. Postoperative pathologic report described a cystic formation lined with pseudostratified ciliated columnar epithelium, with the presence of goblet cells and some areas of cuboidal epithelium (Fig. 3).

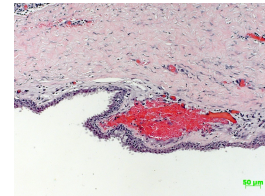
The patient was followed up postoperatively for 1 year, during which the wound was observed to have healed well with no signs of cystic recurrence. A follow-up CT scan showed no significant change to the dimensions of the bony defect.

## DISCUSSION

Surgical ciliated cysts usually occur after radical sinus surgery for maxillary sinusitis and are most often located in the maxillary alveolar region.<sup>2,3</sup> Some authors have reported surgical ciliated cysts that also occurred after orthognathic surgery in the middle of the palate and over the mandibular ramus, chin, infraorbital rim, and medial canthal region.<sup>1,4-7</sup> With regard to their pathogenesis, most authors have suggested that the lesion originates from the trapping of the sinus or nasal mucosa in the wound after surgical procedures.<sup>2,3</sup> Recommendations have been proposed to suture any tearing of the sinus or nasal mucosa before osteosynthesis, to clean or change



**FIGURE 2.** Three-dimensional CT scan showing a bony defect at the upper part of the right frontal process of the maxilla and several titanium plates at the midfacial region.



**FIGURE 3.** Histologic view of the cyst wall showing pseudostratified ciliated columnar epithelium with some goblet cells (hematoxylin and eosin, original magnification  $\times 40$ ).

the saw before performing new osteotomies after cutting the sinus mucosa, and to irrigate the surgical site sufficiently before closure.<sup>3,4,6</sup>

Several cases of these cysts have occurred after maxillofacial fracture surgery.<sup>6,8</sup> Basu et al<sup>9</sup> suggested that such postoperative cysts might be increasing in accordance with the increased incidence of fractures involving the middle third of the face, but this has not been confirmed in the literature. In addition to this patient, 2 other patients with surgical ciliated cysts have been diagnosed and treated in our department. One patient was a 40-year-old man who developed a cyst 4 years after radical sinus surgery, and the other was a 30-year-old man who developed a cyst after a Le Fort I osteotomy 9 years ago for an old facial fracture.<sup>10</sup>

In the literature, surgical ciliated cysts located at the medial canthus region are relatively rare. Sugar et al<sup>7</sup> reported a single case of a cyst located at the medial canthal region after a Le Fort III osteotomy, which presented with a secondary infection. The patient in this article had undergone surgery 10 years ago for a midfacial fracture, and the cyst had developed as a result of the implantation of mucosa from the nasal cavity or ethmoid sinus between the right frontal process of the maxilla and the right nasal bone. There was no infection in this patient. Preoperative CT images showed that the base of the cyst was a bony defect at the right medial canthal region, which did not involve the ethmoid sinus. We conclude that the location of mucosal implantation was not deep and that the cyst grew outward.

## REFERENCES

- Shakib K, McCarthy E, Walker DM, et al. Post operative maxillary cyst: report of an unusual presentation. *Br J Oral Maxillofac Surg* 2009; 47:419-421
- Leung YY, Wong WY, Cheung LK. Surgical ciliated cysts may mimic radicular cysts or residual cysts of maxilla: report of 3 cases. *J Oral Maxillofac Surg* 2012;70:e264-e269
- Cano J, Campo J, Alobera MA, et al. Surgical ciliated cyst of the maxilla. Clinical case. *Med Oral Patol Oral Cir Bucal* 2009;14:e361-e364
- Bourgeois SL Jr, Nelson BL. Surgical ciliated cyst of the mandible secondary to simultaneous Le Fort I osteotomy and genioplasty: report of case and review of the literature. *Oral Surg Oral Med Oral Pathol Oral Radiol Endod* 2005;100:36-39
- Koutlas IG, Gillum RB, Harris MW, et al. Surgical (implantation) cyst of the mandible with ciliated respiratory epithelial lining: a case report. *J Oral Maxillofac Surg* 2002;60:324-325
- Hayhurst DL, Moening JE, Summerlin DJ, et al. Surgical ciliated cyst: a delayed complication in a case of maxillary orthognathic surgery. *J Oral Maxillofac Surg* 1993;51:705-708
- Sugar AW, Walker DM, Bounds GA. Surgical ciliated (postoperative maxillary) cysts following mid-face osteotomies. *Br J Oral Maxillofac Surg* 1990;28:264-267
- Shuttleworth FN, King PF. Pyocele of the orbit following fracture of the maxilla. *Br J Ophthalmol* 1951;35:427-430
- Basu MK, Rout PG, Ripin JW, et al. The post-operative maxillary cyst. Experience with 23 cases. *Int J Oral Maxillofac Surg* 1988;17:282-284
- Tao G, Chi M, Xin P. Maxillary surgical ciliated cyst: report of two cases. *China J Oral Maxillofac Surg* 2005;3:265-267