

A novel technique for measurement of dentogingival tissue by cone beam computed tomography



Jie Cao, DMD,^a Wen-Jie Hu, DMD, PhD,^a Hao Zhang, DMD,^b Deng-Gao Liu, DMD, PhD,^c Di Le, DMD,^d Gang Yang, DMD,^a and Kwok-Hung Chung, DDS, PhD^e

Objectives. To develop a novel technique to visualize dentogingival profiles by using cone beam computed tomography (CBCT) and to evaluate the accuracy of mucogingival tissue thickness measurements with CBCT, as compared with direct measurements *in vitro*.

Methods. A silicone matrix loaded with radiopaque impression material was prepared before performing CBCT on a patient. Two dry cadaver mandibles with simulated mucogingival tissue and six segmental cadaver jaws were used to assess the accuracy of mucogingival tissue thickness measurements directly and radiographically with CBCT images. Paired *t* tests were used to evaluate the intra- and interexaminer reliability and to compare the data between direct and CBCT imaging measurements at $\alpha = 0.05$.

Results. No statistically significant differences were observed between direct and CBCT imaging measurements of simulated mucogingival tissue thickness in mandibular models and in cadaver jaws ($P > .05$). Results of direct measurements with simulated mucogingival tissue thickness indicated good intra- and interexaminer reliability.

Conclusions. A novel technique was developed to obtain mucogingival tissue thickness data on the use of radiopaque impression materials and CBCT imaging. This new method provides a reliable visual dentogingival profile and a means to objective measurements. (Oral Surg Oral Med Oral Pathol Oral Radiol 2015;119:e82-e87)

Cone beam computed tomography (CBCT) has been widely used in several dental specialties, including periodontics, orthodontics, and implant therapy, and it has become an essential tool in diagnostic dentistry.^{1,2} CBCT technology offers high-quality diagnostic images and is considered the definitive tool for evaluating hard tissues of the maxillofacial complex.³ However, it has been reported that CBCT is not suitable for evaluating soft tissues due to its low resolution of density and contrast, which are necessary in the discrimination of soft tissues.⁴ Traditionally, transgingival probing or bone sounding has been widely applied to measure mucogingival tissue, but this technique suffers a great disadvantage and limitation because it is invasive and must be performed with the patient under local anesthesia.⁵ Müller and colleagues applied a noninvasive ultrasonic device to measure mucogingival tissue

thickness and found that both determining correct position and attaining reproducible results were difficult by this method.⁶ Recently, a few studies on visualization and measurement of both hard and soft tissues with CBCT technology have been published. Januario et al.⁷ reported that CBCT could be used for visualizing and measuring dentogingival tissue, applying it in the assessment and measurement of palatal masticatory mucosa.⁸ Fu et al.⁹ evaluated tissue biotypes of cadaver heads radiographically with CBCT scans using an i-CAT machine (Imaging Sciences Int., Hatfield, PA), which adopted a relatively higher radiation dose; however, the contour of dentogingival tissues were not sufficiently distinguishable. The purpose of this study was to develop a method for improved visualization of dentogingival profiles using CBCT scanning and to evaluate the accuracy of mucogingival tissue thickness measurements obtained via CBCT imaging compared with direct measurements *in vitro*.

This study was partially supported by Capital Medical Development and Research Fund, PRC (2011-4025-04), and the project sponsored by Scientific Research Foundation for the Returned Overseas Chinese Scholars, State Education Ministry, PRC (2012-45).

^aDepartment of Periodontics, School and Hospital of Stomatology, Peking University, Beijing, China.

^bDepartment of Prosthodontics, School and Hospital of Stomatology, Peking University, Beijing, China.

^cDepartment of Radiology, School and Hospital of Stomatology, Peking University, Beijing, China.

^dDepartment of General Dentistry, School and Hospital of Stomatology, Peking University, Beijing, China.

^eDepartment of Restorative Dentistry, University of Washington, Seattle, Washington, USA.

Received for publication Jul 4, 2014; returned for revision Oct 22, 2014; accepted for publication Oct 29, 2014.

© 2015 Elsevier Inc. All rights reserved.

2212-4403/\$ - see front matter

<http://dx.doi.org/10.1016/j.oooo.2014.10.022>

MATERIALS AND METHODS

Fabrication procedures

A patient selected as a study subject for replacement of missing maxillary posterior teeth with implants

Statement of Clinical Relevance

By using radiopaque impression technique, a novel technique is developed to visualize and measure mucogingival dimensions by using cone beam computed tomography (CBCT).

required a CBCT scan for treatment planning purposes. Written informed consent was obtained from the patient. The maxillary anterior sextant was selected for mucogingival tissue thickness measurements. A conventional alginate impression of the maxillary arch was made and cast with dental stone (Die-Stone, Heraeus Kulzer, Hanau, Germany). A matrix, including mesial sides of the maxillary first premolars, was fabricated on the cast with silicone putty material (RAPID Soft, Coltène/Whaledent AG, Altstätten, Switzerland). The thickness of the silicone matrix was approximately 6 mm, with at least 8 mm of material extending apically from the free gingival margins facially and lingually. After a 10-minute bench set, the silicone matrix was removed from the cast, and the intaglio surface was trimmed evenly with a scraper to remove a thin layer of silicone material from the surface opposing the mucogingival region of the cast in order to create approximately 1 mm of relief space. The putty-wash impression technique was used, and the final impression was made by using a mixture of barium sulfate powder (Reagent grade, Qingdao Dongfeng Chemical, Qingdao, China) and alginate material (Heraeus Kulzer) in a ratio of 1:2 by weight, loaded into the prepared matrix to capture the detail of the mucogingival tissue contour. The impression was allowed an intraoral setting time of 3 minutes. With the matrix in place, a scan of the maxillary arch and dentition was obtained with the CBCT machine (3 DX multi-image micro-CT scanner, MCT-1, Morita, Kyoto, Japan) at the Radiology Department, Peking University and School of Stomatology, at 80 kV and 6.2 mA for 17 seconds (voxel size: 0.125 mm; gray-scale: 256 bits; focal spot: 0.5 mm; field of view: 4 cm × 3 cm). Reconstructed images were generated and processed using the computer software package I-Dixel-3 DX (Version 1.68, Morita) (Figure 1).

Simulated mucogingival tissue models

Direct measurements. Two dry cadaver mandibles obtained from the Department of Anatomy, Peking University, containing a total of 6 molars and 8 incisors, were used. Two layers of baseplate wax (Dental base plate wax, Shanghai Medical Instruments, Shanghai, China), approximately 2 mm in thickness each, were adapted to cover the area from the alveolar crest to the lower border of the body of the mandible, simulating the mucogingival tissue. Thirty-six holes were punched using a flat-ended (1 mm in diameter) 19-gauge needle (RD Precisionglide, Sigma-Aldrich Co., St. Louis, MO). The holes were located approximately 5 mm apical to the free gingival margin along the long axis of the tooth perpendicular to the bony surface buccally and lingually. Direct measurements of the depth of the holes

were independently conducted by two examiners (JC and MZ) using a caliper (Absolute 500-196, Mitutoyo Co. Kawasaki, Japan), a 19-gauge needle, and a rubber stopper (Dentsply Tulsa Dental Specialties, Tulsa, OK).

CBCT imaging measurements. After direct measurements of the depth of each hole were taken, a final wash impression was made with a silicone matrix by using the materials and methods previously described. A CBCT scan was performed after the initial setting of the mixed impression material. Scans were obtained at 60 kV and 3.0 mA, and the images were constructed using I-Dixel-3 DX (Version 1.68; Morita). After three-dimensional imaging reconstruction, the long axis of each hole in the image was adjusted to parallel the x-axis of the image (sagittal axis). The x-axis was adjusted to coincide with the midline of the selected hole. The mixtures of opaque agent and the impression material within holes and on surfaces of the simulated mucogingival tissue appeared radiopaque. In the sagittal section views, the linear distance between the inner radiopaque surface and cortical bone represented the depth of the hole and thickness of the simulated mucogingival tissue (Figure 2). All imaging measurements were independently obtained by an examiner (JC) and a radiologist (DGL). In addition, all CBCT imaging measurements were repeated 1 week later by the examiner (JC).

Mucogingival tissue thickness of cadaver jaws

CBCT imaging measurements. Six formalin-preserved segmental cadaver jaws (2 maxillae and 4 mandibles, containing 30 interdental papillae) provided by the Oral Pathology Department, School and Hospital of Stomatology, Peking University, were used. Construction and preparation of silicone matrix were performed by using previously described procedures. Square holes (2 mm × 2 mm) were punched perpendicularly through the silicone matrix toward the interdental papillae regions with the use of a puncher. The final wash impression procedure with alginate material mixed with opaque agent was performed, and CBCT scanning was conducted at 60 kV and 3.0 mA. Images were reconstructed and selected, with square holes appearing as radiopaque shadows. The edges of each square were adjusted to parallel to x-, y-, and z-axes respectively. The sagittal axis through the edge of the square was selected as the target axis. The points at both the upper and lower left outer corner of each square hole were chosen to be the starting points for gingival measurement following the target axis. A total of 59 sites were measured by one examiner (JC). In the sagittal section views and measurements, the distances between inner radiopaque surfaces represented the thickness of gingival papillae (Figure 3).

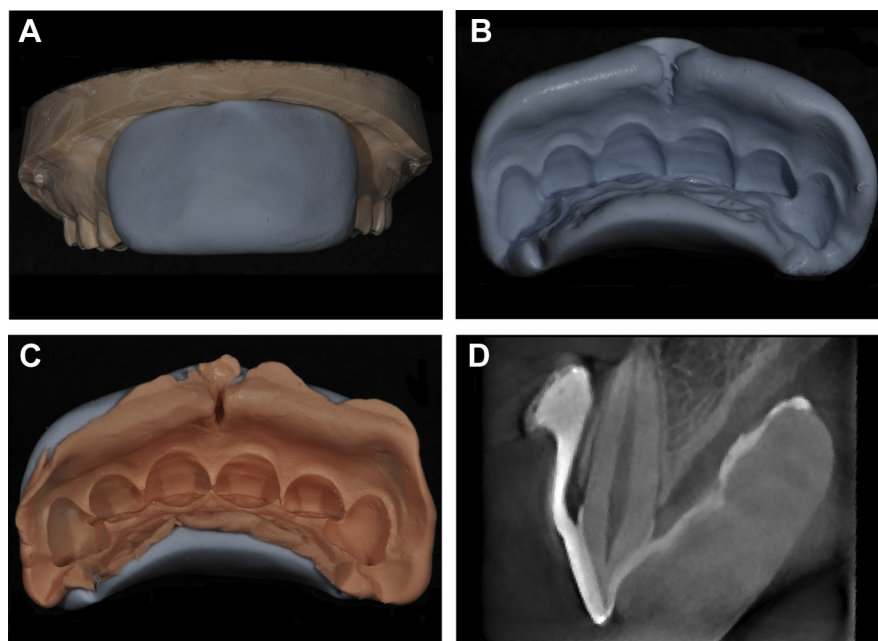


Fig. 1. Fabrication procedures. **A**, Silicone matrix was fabricated on the cast. **B**, Silicone matrix before relief space preparation. **C**, Final wash impression using silicone matrix with mixed opaque agent and alginate material. **D**, Reconstructed cone beam computed tomography image showing sagittal section of dentogingival profile of the upper right central incisor.

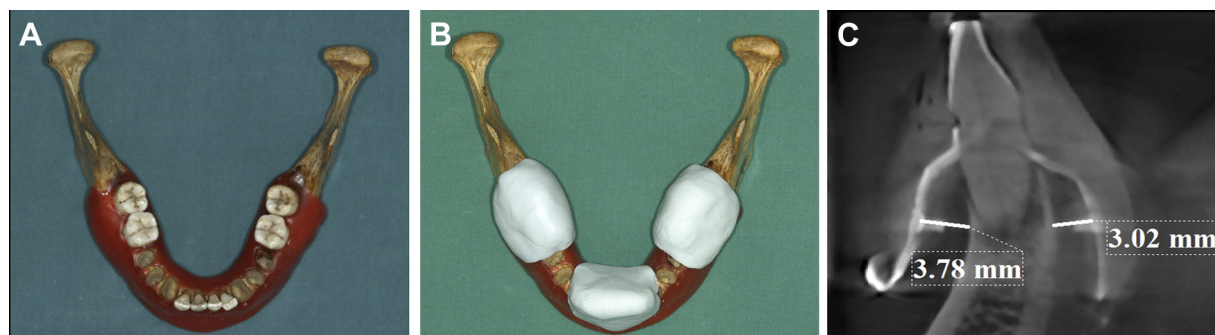

Fig. 2. Simulated mucogingival tissue model for measurement use. **A**, Simulated mucogingival tissue constructed with wax. **B**, Mandibular model with the silicone matrices in place. **C**, Reconstructed cone beam computed tomography image showing sagittal section of depth of punch holes and thickness of mucogingival tissue measurements of a central incisor.

Direct measurements. The matrix with final wash impression material on the segmental cadaver jaws was removed from the specimens after the CBCT scan. The lingual side of each matrix was modified with trimming to expose all lingual gingival papillae and reinserted on the segmental jaw accordingly. A #25 endodontic K-file (Dentsply Tulsa Dental Specialties) was used to measure the mucogingival thickness directly at the sites corresponding to the CBCT measurement sites. The distances were measured with a caliper (Absolute 500-196, Mitutoyo Co.) from the surface of the square to the surface of gingival papillae (D1) and penetration through soft tissue to the lingual papilla surface (D2) was marked with a rubber stopper (Dentsply Tulsa Dental Specialties). The thickness of interproximal

gingival tissue (D) was calculated using the formula: $D = D2 - D1$.

Statistical analyses

Data were analyzed with the statistical software package SPSS (version 16.0, IBM, Chicago, IL). Paired *t* tests were performed to assess intra- and interexaminer reliability and to compare the data between direct and CBCT imaging measurements at $\alpha = 0.05$.

RESULTS

Simulated mucogingival tissue thickness measurements are listed in Table I. The mean and standard deviation of direct and CBCT imaging measurements of simulated

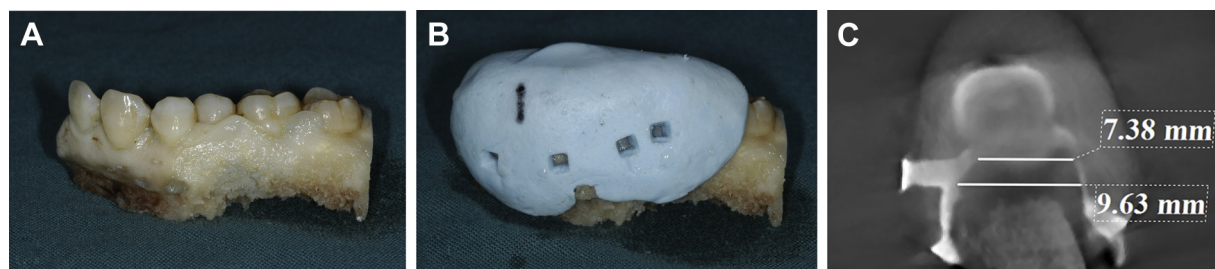


Fig. 3. Cavader jaw model for mucogingival tissue thickness measurements. **A**, Segmental cadaver jaw. **B**, Silicone matrix with punched holes. **C**, Cone beam computed tomography imaging measurement of the mucogingival tissue thickness at target axis of a square hole.

Table I. Data of direct and cone beam computed tomography measurements of simulated mucogingival tissue thickness

	Direct measurement (mm)		CBCT imaging measurement (mm)		
	Examiner 1	Examiner 2	Radiologist	Examiner 1	Examiner 1 (1 week later)
	3.57	3.58	3.58	3.57	3.64
	3.71	3.74	3.63	3.57	3.57
	3.73	3.71	3.78	3.72	3.71
	3.78	3.78	4.03	3.94	3.98
	3.77	3.77	3.62	3.65	3.72
	3.72	3.78	3.70	3.70	3.67
	3.39	3.53	3.48	3.45	3.46
	3.44	3.45	3.32	3.32	3.32
	3.02	3.02	3.09	3.05	3.02
	3.36	3.30	3.28	3.25	3.33
	3.66	3.70	3.31	3.39	3.39
	3.74	3.62	3.78	3.65	3.65
	4.07	3.99	3.99	4.07	4.10
	4.07	3.97	4.14	4.25	4.08
	3.84	3.85	3.90	3.93	3.86
	3.88	3.79	3.90	3.88	3.84
	3.76	3.63	3.72	3.54	3.64
	3.72	3.58	3.53	3.76	3.75
	3.27	3.36	3.41	3.29	3.28
	3.18	2.99	3.20	3.16	3.18
	3.60	3.73	3.65	3.61	3.61
	3.70	3.47	3.63	3.61	3.63
	3.57	3.54	3.55	3.52	3.56
	3.75	3.17	3.75	3.75	3.75
	3.54	3.78	3.44	3.44	3.51
	2.64	3.47	2.69	2.76	2.72
	3.23	2.67	3.25	3.21	3.28
	3.33	3.17	3.33	3.22	3.28
	2.74	3.36	2.69	2.70	2.64
	2.82	2.84	2.54	2.58	2.54
	2.78	2.92	2.74	2.67	2.69
	2.90	2.97	2.91	2.98	2.96
	3.39	3.06	3.44	3.40	3.40
	3.67	3.36	3.66	3.76	3.69
	3.43	3.25	3.42	3.38	3.31
	2.67	2.88	2.76	2.82	2.76
Mean	3.46	3.44	3.44	3.43	3.43
Standard deviation	0.39	0.35	0.40	0.40	0.41

mucogingival tissue thickness were 3.46 ± 0.39 mm and 3.43 ± 0.40 mm, respectively. The data displayed good intraexaminer reliability ($P = .927$) and inter-examiner reliability ($P = .672$) (Table II). The mean

and standard deviation of mucogingival tissue thickness on segmental cadaver jaws for direct and CBCT imaging measurements were 7.90 ± 1.29 mm and 8.16 ± 1.47 mm, respectively. No statistically significant

Table II. Comparison of direct and cone beam computed tomography (CBCT) measurements of simulated mucogingival tissue thickness

Variable	P	Significance
Examiner 1 week later Repeat CBCT measurements	.927	NSSD*
Examiner 1 vs Examiner 2 in direct measurements	.672	NSSD
Examiner 1 vs radiologist in CBCT measurements	.538	NSSD
Direct measurements vs CBCT measurements	.174	NSSD

*NSSD: Nonstatistically significant difference ($P > .05$).

differences were observed between direct and CBCT imaging measurements of simulated mucogingival tissue thickness ($P = .174$) and mucogingival tissue thickness of cadaver jaw ($P > .05$).

DISCUSSION

This study describes a novel and noninvasive technique based on CBCT imaging, in which a mixture of opaque agent and alginate impression material was used to aid visualization of the dentogingival profile. The consistency of opaque agent mixed with alginate impression material maintains adequate flowability and adaptation to the dentogingival surface and interdental papilla areas intraorally. During CBCT scanning, the mucogingival tissue was already covered by a thin layer of opaque agent mixed with alginate impression material that had been loaded inside the silicone matrix with relief space in advance (Figure 4). According to previous studies, visualization of soft and hard tissues of the dentogingival unit was accomplished by means of CBCT with soft tissue retraction (lips and cheeks).⁷ However, results revealed that the capability to discriminate soft tissues by CBCT along with soft tissue retraction was limited. Subsequently, the i-CAT system has been used to capture the dentogingival unit. Nevertheless, the resulting scans provide only qualitative and not quantitative measurement because the differences between most lower density tissues and connective tissues cannot be effectively visualized on the images.⁸ The present technique was not restricted by the limitations of different CBCT systems and local environmental factors because a silicone matrix and radiopaque impression material were applied. The technique described in this study provides high-quality images of hard (teeth and alveolar bone) and soft (facial and palatal mucogingiva) tissue profiles with better contrast and optimal resolution and allows precise measurements of the dimensions and relationships of these structures. This technique can be used in diagnosis and for treatment planning in periodontal and implant therapy because both hard and soft tissue

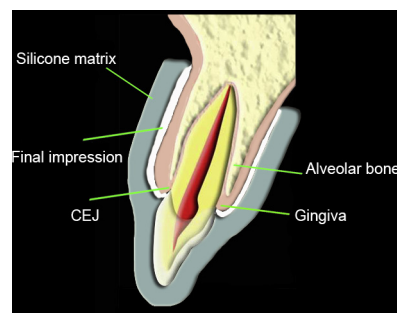


Fig. 4. Schematic drawing of cone beam computed tomography image to show the dentoalveolar and mucogingival tissue structure using radiopaque impression technique.

profiles can be demarcated in a single CBCT scanning procedure. In addition, CBCT images can be stored and printed, and repeat measurement can be performed either on the computer screen or on hard copies of the images. Owing to the nature of the CBCT scan, images of the same location or region can be retrieved repeatedly at different time points with the same settings. Therefore, this technique not only produces high-resolution images but also allows for repeating measurements of the mucogingival tissue thickness and comparison of data without time limitation. Traditional methods, such as transgingival probing and ultrasonic device use, do not feature similar advantages.^{5,6,10} This new, noninvasive method requires preparation of a study cast and silicone matrix as well as mixture of opaque agent contained impression material before CBCT scanning; thus, an extra visit by the patient should be scheduled in advance in a clinical setting where this method is used.

The linear CBCT measurement accuracy of hard tissues has been proven in many studies. Mish et al. showed that there was no statistically significant difference between direct measurements and CBCT imaging measurements on examination of periodontal defects.¹¹ However, only a few studies have assessed the accuracy of linear measurements of soft tissues by CBCT scan.^{7,8} The accuracy of this proposed technique was validated by using simulated mucogingival tissue models and cadaver jaws with direct and CBCT imaging measurement procedures and determined to have no statistically significant differences ($P > .05$) (Table II). This indicates that the proposed technique can replace other invasive procedures, such as transgingival probing and bone sounding, in a clinical setting.

CONCLUSIONS

By using radiopaque impression material, a novel technique is described to aid in the visualization and measurement of dentogingival dimensions via CBCT

scanning and imaging. Repeated measurements of CBCT images of mucogingival tissues thickness demonstrated no significant differences and were highly reproducible.

The authors thank Dr. Hai-Yan Luo in the Pathology Department, School and Hospital of Stomatology, Peking University, for the collection of segmental cadaver jaws; and Dr. Huan-Xin Meng, and Drs. Tijana Stijacic and Hollie Walsh for assistance in preparing this manuscript.

REFERENCES

1. Mozzo P, Procacci C, Tacconi A, et al. A new volumetric CT machine for dental imaging based on the cone-beam technique: preliminary results. *Eur Radiol.* 1998;8:1558-1564.
2. De Vos W, Casselman J, Swennen GR. Cone-beam computerized tomography (CBCT) imaging of the oral and maxillofacial region: a systematic review of the literature. *Int J Oral Maxillofac Surg.* 2009;38:609-625.
3. Scarfe WC, Farman AG, Sukovic P. Clinical applications of cone-beam computed tomography in dental practice. *J Can Dent Assoc.* 2006;72:75-80.
4. Kobayashi K, Shimoda S, Nakagawa Y, et al. Accuracy in measurement of distance using limited cone-beam computerized tomography. *Int J Oral Maxillofac Implants.* 2004;19:228-231.
5. Greenberg J, Laster L, Listgarten MA. Transgingival probing as a potential estimator of alveolar bone level. *J Periodontol.* 1976;47:514-517.
6. Müller HP, Schaller N, Eger T, et al. Thickness of masticatory mucosa. *J Clin Periodontol.* 2000;27:431-436.
7. Januario AL, Barriviera M, Duarte WR. Soft tissue cone-beam computed tomography: a novel method for the measurement of gingival tissue and the dimensions of the dentogingival unit. *J Esthet Restor Dent.* 2008;20:366-373.
8. Barriviera M, Duarte WR, Januario AL, et al. A new method to assess and measure palatal masticatory mucosa by cone-beam computerized tomography. *J Clin Periodontol.* 2009;36:564-568.
9. Fu JH, Yeh CY, Chan HL, et al. Tissue biotype and its relation to the underlying bone morphology. *J Periodontol.* 2010;81:569-574.
10. Eger T, Müller HP, Heinecke A. Ultrasonic determination of gingival thickness. Subject variation and influence of tooth type and clinical features. *J Clin Periodontol.* 1996;23:839-845.
11. Misch KA, Yi ES, Sarment DP. Accuracy of cone beam computed tomography for periodontal defect measurements. *J Periodontol.* 2006;77:1261-1266.

Reprint requests:

Wen-Jie Hu, DMD, PhD
Department of Periodontics
School and Hospital of Stomatology
Peking University
22 S Zhongguancun Ave
Haidian District, Beijing
China 100081.
Huwenjie@pkuss.bjmu.edu.cn